

Departmental Protocols Including Referral Criteria for Plain Image Radiography for Primary Care Referrals.

CONTROLLED DOCUMENT

CATEGORY:	Procedural document.
CLASSIFICATION:	Clinical.
PURPOSE	Referral criteria for plain film imaging as required under IR(ME)R 2017.
Controlled Document Number:	CG1302
Version Number:	1.3
Controlled Document Sponsor:	Consultant Radiologist/Clinical Service Lead
Controlled Document Lead:	General Manager for Radiology
Approved By:	Clinical Director Division 1B.
On:	August 2022 *Amended April 2023*
Review Date:	August 2025
Distribution:	
<ul style="list-style-type: none"> • Essential Reading for: All Imaging staff. GP Practices. • Information for: All Staff. 	

Contents.

Introduction.....3

Thorax.....5

Skull and Face.....7

Abdomen.....8

Pelvis.....9

Cervical Spine.....10

Thoracic Spine.....11

Lumbar Spine.....13

Upper extremity.....15

Lower extremity.....18

Foreign Bodies.....20

Ingestion or suspected ingestion of
extra strong rare earth magnets.....21

.

Appendices.

Appendix 1
Imaging services.....22

Appendix 2
Brain Imaging Pathway and Neurology Advice and Guidance.....25

Introduction.

The purpose of this document is to assist the GP or IRMER qualified practitioners in making a referral for plain x-ray imaging and to give support regarding referral pathways. The document also supports radiographers in the vetting of requests prior to imaging to ensure compliance with IRMER guidelines. Radiographers will also access this document to ensure the correct projections are being undertaken for each request.

The Ionising Radiation (Medical Exposure) Regulations 2017 have a significant impact on the requesting, reporting and management of referrals to imaging. Under the legislation the referrer must supply sufficient medical information to enable the practitioner to justify the exposure. It is intended that the following protocols will assist the referrer and operator to ensure that the patient receives an exposure to radiation only when the result will affect the management of that patient.

A. The referrer must:

- Ensure the patient they are referring is the correct patient. This means double checking that the clinical details and examination required are correct for the name
- Provide sufficient information so that the patient can be uniquely identified i.e. name, date of birth, address and hospital number
- Supply sufficient medical data and a clear clinical question to enable an x-ray or scan to be justified
- Supply their own details, including a reliable contact number and a signature

GP referral requests via the practice nhs.net account must have the GP's physical signature.

If there is no physical signature the GP must clearly state their name on the request. This request must come from the GP's own nhs.net email address. The referrer name on the nhs.net email address must be the same as referrer on the request.

The requests will be scanned into CRIS with a note to confirm that the request has come from the referrers email address; the email address of the referrer will also be added at this point.

- B. Should a referral need to be cancelled, the department must be contacted directly and a member of staff spoken to immediately. Electronic requests cannot be cancelled using the electronic referral system.
- C. Referrers must ensure that duplicate requests are not entered into the system.
- D. Any urgent requests out of hours require the referrer to telephone to discuss with staff as well as providing the referral (paper or electronic).

The sharing of Usernames/Passwords is not acceptable and will not be condoned by UHB NHS Trust or any of its employees. This includes logging in on behalf of another staff member. GPs/staff members who are found to fail to

abide by this condition will have their access revoked and this will be raised as a formal breach.

A period of account inactivity of 3 months or more will result in access being revoked.

The Trust is authorised to undertake spot checks on the 3rd party at any time in order to check national compliance and/or completion of Local Confidentiality Agreement and/or IG training compliance.

All staff where access is being requested must sign a Local Confidentiality Agreement which must be held by the GP practice and available to view at any time.

IT IS THE RESPONSIBILITY OF THE GP PRACTICE TO ADVISE US WHEN STAFF LEAVE AS SOON AS POSSIBLE SO THAT WE CAN REMOVE THEIR ACCESS TO YOUR SITE'S PATIENT DATA.

If the request card is incomplete or illegible, legally the examination cannot be performed.

For all x-ray examination the operator (radiographer) must ensure:

- An Imaging Department request form has been completed
- Correct identification of the patient (Procedures for Medical Imaging, procedure 2)
- LMP check where appropriate (Procedures for Medical Imaging, procedure 4)
- Where appropriate, the patient is changed into a radiolucent gown with all radiopaque objects removed from the area of interest
- A full explanation of the procedure is given to the patient
- Any previous radiographs are available prior to the examination
- The correct radiographic views are undertaken – refer to departmental protocols and referral criteria
- The appropriate exposure is selected – refer to exposure charts
- The radiation dose is as low as reasonably practicable
- Dose Area Product (DAP) or exposure details are recorded on the RIS
- The operator name and number of exposures are recorded on the RIS

If there are any concerns about a radiological request, please seek the advice of a radiologist via the Advice and Guidance Pathways (A&G), Appendix 1.

Thorax (CXR)

Request	Referral Criteria	View	Comments
Chest.	Chest pain, short of breath, cardiac disease, hypertension, haemoptysis, follow-up pneumonia, malignancy, cough for longer than 3 weeks, Pleural effusion, mediastinal or lung base pathology.	PA/AP*.	<p>If there is an abnormality on a frontal chest radiograph that needs to be clarified, the standard investigation for this is now CT scanning and not a lateral chest radiograph.</p> <p>Lateral radiographs can still be performed to evaluate cardiac pacemakers post-insertion and occasionally in specific cases to evaluate the position of a drain or other medical device.</p> <p>Lateral radiographs can be performed at the direction of a radiologist and in this case the radiologist concerned should report the examination.</p>
	Trauma.	PA/AP*.	In the context of major trauma, ED referral and CT scan of the chest will be indicated. A CXR is useful to exclude pneumothorax if clinically suspected. CXR should not be requested to look for rib fractures.
	Chest for Nipple markers	PA	To be arranged by the reporter at the time of reporting. The radiographer must arrange for an urgent report when the patient re-attends. The report should be emailed to the GP to avoid delay.
	Foreign bodies.	PA.	Inspiration.
	Pneumothorax.	PA.	Inspiration only.
NOTES	* AP chest only if PA chest is impossible		

Thorax

Request	Referral Criteria	View	Comments
Ribs.	Trauma.	PA (CXR).	In general CXR should not be requested to specifically look for rib fractures. CXR is useful to exclude pneumothorax if clinically suspected. However multiple rib fractures may indicate significant injury in the appropriate context. Most of these patients will usually require hospital referral.
Thoracic inlet.	Goitre, dyspnoea, trachea/bronchial, carcinoma, orthopnoea.	PA, Lateral.	Seek appropriate radiologist Advice & Guidance. Cone to include the trachea bifurcation. Employ valsalva manoeuvre. Lateral to show to the level of the bifurcation of the trachea, please include a soft tissue lateral neck if area not demonstrated.
Sternum.	Trauma - including mechanism Sternal swelling.	Lateral. PA/AP chest.	
Sterno-clavicular joints.	Trauma or non traumatic swelling of a medial clavicle.	AP. Cranial angulated view of both clavicles.	Radiologist Advice and Guidance for additional imaging.
Radiographer Note		A PA chest projection should always be obtained with the maximum inspiratory effort. Images need to be taken without rotation.	

Skull and Facial Bones

Request	Referral Criteria	View	Comments
Skull.	Lump.	Tangential view.	Collimate to include a bony landmark on the skull, to allow the referrer/reporter to orientate the position of the lump. External foreign body marker to be used as appropriate. Skull not indicated for pituitary lesion, dementia, CVA, SOB, headache, epilepsy. Follow brain imaging pathway and neurology advice and guidance, Appendix 2
Orbits.	See Foreign Bodies section below.		
Facial bones.	Orbital blunt trauma, mid facial trauma.	OM. OM30°. Modified SMV – 'jug handle' –for zygoma.	
Nasal bones.	Not indicated.		May request additional view of OM 20° . Specialist referral only (A/E consultant, ENT or maxillofacial specialist).
Sinuses.	Not indicated.	OM (open mouth) PA 15°.	Specialist referral only. Mucosal thickening is a non specific finding and may occur in asymptomatic patients.
Mandible.	Mandibular Trauma, Non-traumatic TMJ problems. Cyst/abscess, Suspected tumour. Dental abscess and loose dentition assessment. Orthodontic assessment.	PA Mandible and OPG. OPG. OPG. OPG and lateral cephalostat.	RT and LT Lateral oblique if OPG not possible.
TMJ.	TMJ Dysfunction.	OPG, TMJ's open	Referrer should seek appropriate radiologist Advice & Guidance.

		and closed.	
Parotid Gland.	Not indicated.	Tangential, AP, Lateral, oblique, Mandible.	Plain imaging is not routinely indicated. US is advised if there is a clinical suspicion of calculus or occluded salivary duct.
Sub-mandibular Gland.	Not indicated.	Tongue depressed lateral.	Plain imaging is not routinely indicated. US is advised if there is a clinical suspicion of calculus or occluded salivary duct.

Abdomen

Request	Referral Criteria	View	Comments
Abdomen/ KUB.	?renal calculi. ?foreign body.	Supine.	If there is a high clinical suspicion for renal calculus consider CTKUB in the first instance via radiologist advice and guidance. Only used for follow up of known calculi. AXR is not indicated for suspected appendicitis or gastro-intestinal haemorrhage AXR for constipation not routinely indicated but may assist management in certain limited circumstances (e.g. elderly care).
Abdomen	Lost Intra Uterine Contraceptive device (ICUD) following a negative ultrasound scan ONLY	Supine	

Pelvis

Request	Referral Criteria	View	Comments
Pelvis and Hip.	Trauma with inability to weight bear or pain. Suspected fractured neck of femur. Suspected dislocation of hip. Painful prosthesis. Bone pain, arthropathy, hip pain.	AP pelvis, Lat hip. AP pelvis, Lat hip. AP pelvis, Lat hip. AP pelvis. AP pelvis.	All prosthesis should be included. Horizontal beam lateral for history of trauma. Whole of cement +/- ball bearing if in situ. Generalised pain with NO history of trauma- turned lateral hip. SEE RED FLAGS BELOW TO ENSURE URGENT APPOINTMENT, REFERRAL AND VETTING CRITERIA. URGENCY CODE 7. THESE CASES REQUIRE AN URGENT REPORT.
Sacroiliac joints.	Pain, suspected SIJ lesion.	PA 10°↓,	MRI may help in the investigation of seronegative arthropathy. Discuss with appropriate Advice and Guidance.
Paediatric Hips.	Non weight bearing / limping.		See paediatric protocol.
NOTES	Referrers -Hip pain characteristic of osteoarthritis is not an indication for radiography unless symptoms are such that a referral to an orthopaedic surgeon is being considered.		
RED FLAGS	<ul style="list-style-type: none"> • Severe progressive unremitting pain affecting sleep /ability to weight bear +/-: • (Consider avascular necrosis, stress fracture, primary bone tumour) • Deteriorating bone pain around the hip with known Prostate, Breast, Lung, Renal or Thyroid Cancer or suspected myeloma (malaise, unexplained weight loss, night sweats) • Rapid deterioration of symptoms following surgery e.g. total hip replacement • Inflammatory Hip Joint Pain: Morning joint-related stiffness >30 minutes; night pain, stiffness and pain relieved by activity, multiple joints affected, possible systemic symptoms <p>Suspected soft tissue sarcoma. New unexplained soft tissue palpable lump around the hip, increasing in size >3cm, painful and painless</p>		

Cervical Spine

Request	Referral Criteria	View	Comments
Cervical Spine.	Degenerative / spondylotic changes.	AP, Lateral.	<p>Not indicated routinely for neck pain, brachialgia, and degenerative change. Normal plain x-rays may be falsely reassuring.</p> <p>MRI is the imaging of choice if there is a clinical suspicion of worsening radiculopathy, osteomyelitis, primary bone tumour, discitis inflammatory spondylitis ankylosing spondylitis – follow spinal triage pathway. Orthopaedic Triage Service : Birmingham Community Healthcare (bhamcommunity.nhs.uk) See neurological red flags (see below). Refer patient to local ED.</p>
Cervical Spine.	? Cervical rib	AP, lateral	<p>Cone to include C7/T1 junction. Ensure elongated transverse processes and cervical ribs, if present, are fully demonstrated.</p>
Cervical Spine.	Trauma – Neck injury with pain.	<p>Lateral +/- swimmers to demonstrate C7/T1 (see comments).</p> <p>Proceed to AP (C3-C7) and Odontoid (C1-C2) only when C7/T1 has been demonstrated</p>	<p>If there is clinical concern re a cervical fracture then this should be referred to ED as plain radiographs need to be interpreted with clinical findings.</p> <p>Consider specialist referral.</p> <p>If C7/T1 not demonstrated, a lateral swimmers projection should be performed. If this projection does not demonstrate C7/T1 the examination must be ended and the patient referred for CT. No arm pull is to be administered. Do not continue with AP projections.</p>
	Rheumatoid with suspected atlanto-axial	Peg	

Cervical Spine.	instability.	projection, lat flexion & extension.	
NOTES	<p>RED FLAGS FOR NECK PAIN</p> <p>Neurological:</p> <ul style="list-style-type: none"> • Gait disturbance- Widespread neurological deficit • Severe or progressive sensory/motor loss- signs of spinal cord compression • Significant vertebral body tenderness <p>Other:</p> <ul style="list-style-type: none"> • Significant preceding trauma or neck surgery • History of TB, HIV, cancer or inflammatory arthritis – Systemic upset, weight loss, fevers, night sweats • Severe pain/ nocturnal pain not responding to conservative measures • Known malignancy 		

Thoracic Spine

Request	Referral Criteria	View	Comments
Thoracic Spine. Trauma.	Elderly or known osteoporosis patient with thoracic pain and with focal bony tenderness.	AP, Lateral.	<p>If acute trauma with focal bone tenderness consider ED referral.</p> <p>MRI is the imaging of choice for thoracic pain with any focal neurology.</p> <p>Predisposing cause - suspected cancer/inflammation/night pain/long term steroid use) – follow the spinal triage pathway marking referral as urgent, Orthopaedic Triage Service : Birmingham Community Healthcare (bhamcommunity.nhs.uk)</p>

Thoracic Spine. Non trauma.	Suspected osteoporotic compression (crush) fracture.	AP, Lateral.	Plain x-rays should not be used to diagnose degenerative disease. Degenerative changes are common and often unrelated to symptoms
	Pain due to suspected inflammatory condition.	AP, Lateral.	Rheumatology referral should be considered.
	Suspected scoliosis.	AP, Lateral.	Radiologist to confirm. Whole spine imaging available (Heartlands, Good Hope and Solihull sites only).
	Other clinical problems should follow the spinal triage pathway.		<p>Plain x-rays rarely contribute usefully to the management of patients with suspected disc disease or radicular signs. Pain with radicular features should follow the spinal triage pathway Orthopaedic Triage Service : Birmingham Community Healthcare (bhamcommunity.nhs.uk)</p> <p>Disc evaluation or evaluation for possible osteomyelitis/discitis requires spinal triage assessment marking the referral as urgent.</p> <p>In the presence of known previous cancer requires spinal triage assessment marking the referral as urgent. See back pain red flags for further information.</p>

Lumbar Spine

Request	Referral Criteria	View	Comments
Lumbar Spine Trauma.	Trauma with lumbar area pain.	AP, Lateral.	If acute trauma with focal bone tenderness consider ED referral.
Lumbar Spine. Non trauma.	<p>Suspected osteoporotic compression (crush) fracture.</p> <p>Pain due to suspected inflammatory condition</p> <p>Suspected scoliosis.</p> <p>Other clinical problems should follow the spinal triage pathway.</p>	<p>AP, Lateral.</p> <p>AP, Lateral.</p> <p>AP, Lateral.</p>	<p>Plain x-rays should not be used to diagnose degenerative disease. Degenerative changes are common and often unrelated to symptoms</p> <p>Rheumatology referral should be considered.</p> <p>Radiologist to confirm. Whole spine imaging available (Heartlands, Good Hope and Solihull sites only).</p> <p>MRI is advised. Plain x-rays rarely contribute usefully to the management of patients with suspected disc disease or radicular signs. Pain with radicular features should follow the spinal triage pathway Orthopaedic Triage Service : Birmingham Community Healthcare (bhamcommunity.nhs.uk) Disc evaluation or evaluation for possible osteomyelitis/discitis requires spinal triage assessment marking the referral as urgent.</p> <p>In the presence of known previous cancer requires spinal triage assessment marking the referral as urgent.</p> <p>See back pain red flags for further information.</p>
Notes	<p>RED FLAGS FOR BACK PAIN.</p> <p>Neurological:</p> <ul style="list-style-type: none"> • Sphincter and gait disturbance or severe or progressive motor loss • Saddle anaesthesia or widespread neurological deficit 		

Lumbar Spine

Request	Referral criteria	View	Comments
Sacrum.	Trauma.	AP10°↑ Lateral.	Normal appearances are often misleading. Positive findings do not alter the clinical management. See Pelvis for SIJ imaging criteria
Coccyx.	Direct trauma. Pain.	Lateral.	Indicated only in specific circumstances.
Scoliosis.	Alteration in gait/posture.	AP whole spine.	Dedicated units for whole spine scoliosis imaging can be found at GHH and SHH. Patients should be referred to these centres. All requests will be vetted by a radiologist prior to booking the appointment.

Upper Extremity

Request	Referral Criteria	View	Comments
Shoulder.	Primary care to follow the evidence based shoulder pathway from BESS (British Elbow and Shoulder Society): For further shoulder pathways: Patient care pathways and guidelines – British Elbow & Shoulder Society (bess.ac.uk)		
	Trauma.	AP, Axial. +/- Lateral Scapula.	ED referral advised.
	Recurrent dislocation.	AP, Axial.	Seek radiologist Advice and Guidance if considering further imaging modalities.
	Non traumatic pain, eg arthropathy, calcific tendonitis.	AP, Grashey and Axial views.	Grashey - Gleno humeral joint - Patient rotated 45 degrees, centre through the joint. Ultrasound or MRI following referral to secondary care. National Guidelines – British Elbow & Shoulder Society (bess.ac.uk) Primary care access pathway for shoulder pain at UHB
Notes	<p>RED FLAGS FOR SHOULDER PAIN</p> <ul style="list-style-type: none"> • Any history or suspicion of malignancy • Any mass or swelling • Suggestions of infection, e.g. red skin, fever, systemically unwell • Trauma, pain, weakness (? fracture, ? acute cuff tear) • Trauma, epileptic fit or electric shock leading to loss of rotation and abnormal shape (? unreduced dislocation) • Persistent symptoms <p>Consider imaging if symptoms persist following initial physiotherapy and injection of joint. Following radiographs referral to intermediate care/shoulder clinic should be considered.</p>		

Upper Extremity

Scapula.	Trauma.	AP, Lateral.	If AP looks normal, an axial view should be undertaken as an additional view: patient leaning backwards 10°, 15° angle on tube (clavicle must clear apex of lung).
Clavicle.	Trauma.	AP.	If AP looks normal, an axial view should be undertaken as an additional view: patient leaning backwards 10°, 15° angle cranially↑ (clavicle must clear apex of lung).
Acromio-clavicular joint.	Trauma. Suspected subluxation.	Coned AP.	Comparison view of other ACJ may be required only if there is continued concern regarding the affected joint. Weight bearing views are not routinely indicated.
Humerus.	Trauma. Suspected arthropathy Unexplained pain or deformation.	AP, Lateral.	Views must include the head of humerus and elbow on the image.
Elbow.	Trauma. Suspected arthropathy Unexplained pain or deformation Suspected arthropathy.	AP, Lateral.	Comparison views in children must be sanctioned by a radiologist. See paediatric protocol.
Radius/ Ulna.	Trauma. Suspected arthropathy Unexplained pain or deformation.	AP, Lateral.	Must include elbow and wrist joint.
Wrist.	Trauma. Suspected arthropathy Unexplained pain or deformation.	AP, Lateral.	Include metacarpals and distal 1/3 radius and ulna.
Scaphoid.	Trauma.	PA (ulnar deviation), Lateral PA oblique, PA ulna deviation with 30°↑ angulation, AP oblique.	Initial views to include metacarpals and distal 1/3 radius and ulna with wrist in ulna deviation. Cone as per wrist x-ray on AP and lateral views. If scaphoid fracture is clinically suspected then scaphoid views need to be specifically requested.
Hand.	Trauma. Suspected arthropathy	DP, Oblique.	Lateral view for fractured/ displaced metacarpals

	Unexplained pain or deformation.		Soft tissue exposure for FB. Where both hands have been requested, image using separate exposures.
Hand and wrist for bone age.	Developmental delay.	PA hand and wrist NB- <u>The left or Non dominant hand must be imaged.</u>	The middle finger must be in alignment with the wrist, no deviation of the wrist. This should be performed on children one year and over.
Thumb.	Trauma. Suspected arthropathy Unexplained pain or deformation.	AP, Lateral.	Include 1st carpometacarpal joint.
Fingers.	Trauma. Suspected arthropathy Unexplained pain or deformation.	AP/PA, Lateral.	Oblique projection may also be required for follow up patients in strapping.

Lower Extremity

Request	Referral Criteria	View	Comments
Femur.	Trauma. Suspected arthropathy Unexplained pain or deformation.	AP, Lateral.	Must include hip joint and knee.
Knee.	Trauma with inability to weight bear or pronounced bony tenderness. Locking, restrictive movement, effusion, surgical assessment, Knee pain. ? degenerative changes. Patients aged 50 years and over with a clinical question or history of OA or arthritis.	AP, horizontal beam lateral. AP, Lateral. AP, Lateral. AP, Lateral and skyline patella	Trouser legs must not compress the soft tissue or be visible when rolled above the knee. Trousers should be removed if this is not possible. Standing AP projection unless patient is unable. All patients should initially have plain x-rays of the affected joint(s) Supplementary information for access to imaging for non-red flag post traumatic knee patients can be found at: Knee referral flowchart (uhb.nhs.uk)
Tibia and Fibula.	Trauma with inability to weight bear or pronounced bony tenderness. Suspected arthropathy Unexplained pain or deformation.	AP, Lateral.	Must include both knee joint and ankle.
Ankle.	Trauma with inability to weight bear or pronounced bony tenderness. Suspected arthropathy Unexplained pain or deformation.	AP, Lateral.	Include the base of the 5 th metatarsal on the lateral projection. If fractured, x-ray foot. An oblique view may be requested with 45° internal rotation, 30° ↑ angulation.
Calcaneum.	Trauma with inability to weight bear or pronounced	Lateral, Axial.	Not indicated for ?plantar fasciitis

	bony tenderness. Suspected arthropathy Unexplained pain or deformation.		? spur – these indications should have ultrasound as imaging, and not plain radiographs.
Foot.	Trauma with inability to weight bear or pronounced bony tenderness. Suspected arthropathy Unexplained pain or deformation.	DP, Oblique, Lateral View.	Lateral view for dislocation or fracture of the tarsals or metatarsals.
Toes.	Trauma with inability to weight bear or pronounced bony tenderness. Suspected arthropathy Unexplained pain or deformation.	DP, Lateral.	Obliques may be necessary if a lateral is unachievable.
Hallux.	Trauma with inability to weight bear or pronounced bony tenderness. Suspected arthropathy Unexplained pain or deformation. ? Hallux valgus deformity.	DP, Lateral. Weight bearing DP and lateral. Non weight bearing oblique.	Foot projections. Ensure DP and lateral are weight bearing.
Leg length.	Unequal leg length, alignment and surgical planning. ? mechanical axis. ? for high tibial osteotomy(HTO) planning and follow up post surgery. For deformity after fracture or previous joint replacement. Pre-op assessment and follow up. Limb length discrepancy. Complex realignment surgery with external fixation assessment.	AP weight bearing both legs, ASIS to ankle.	Referral to orthopaedic consultant is advised in the first instance. Dedicated units for leg lengths imaging can be found at HGS sites.

Foreign Bodies

Request	Referral Criteria	View	Comments
Skull.	Foreign Body in scalp.	Tangential view.	Use a marker to localise the entry wound.
Orbits.	FB – trauma only. Pre MRI Screening – FB.	OM Eyes up and eyes down. PA 20-25° ↓ ONLY – Eyes up.	If foreign body is seen, perform a lateral projection. One view only to identify presence of metal fragment required.
Throat.	Swallowed Foreign Body.	Lateral.	Soft tissue exposure.
Chest.	Inhaled Foreign Body.	PA.	Inspiration and expiration.
Abdomen.	Swallowed Foreign Body (Only done for sharp objects or batteries).	Supine.	To include diaphragm to rectum.
Upper and Lower Extremities	Penetrating injury. Specify type of foreign body i.e. metallic, glass.	2 views at 90° i.e. AP/PA and Lat centred over the wound. A tangential view may be helpful to localize a foreign body.	Use a marker to localise the entry wound. Remove dressings where appropriate.

NPSA Alert

Ingestion or suspected ingestion of extra strong rare earth magnets.

Request	Referral Criteria	View	Comments
<p>Abdomen +/- Chest.</p>	<p>Ingestion or suspected ingestion of extra strong rare earth magnets.</p> <p>Neodymium magnets (also known as NdFeB, NIB, Neo magnet or Super Strong Rare-Earth Magnets).</p> <p>Rare earth magnets are between five and ten times stronger than ceramic magnets and are sometimes called 'super strong' or powerful magnets.</p>	<p>Erect Chest X-ray and abdominal X-ray (with the patient lying down prone if possible). Image clearly marked as prone or supine.</p> <p>In the case of a single magnet being identified on an abdominal X-ray, a HBL supine abdominal X-ray should also be performed to confirm that only one magnet has been ingested and to check for perforation.</p> <p>DO NOT PERFORM A LATERAL DECIBITUS.</p> <p>A lateral chest x-ray should be performed if a single magnet is seen in the chest.</p>	<p>Follow up abdominal X-ray should be performed at 6-12 hours in those patients who are asymptomatic (only repeat CXR if magnets are seen in the chest on the first image). It is essential that the abdominal radiographs are always performed in the same position (lying down, ideally prone).</p> <p>Repeat imaging may be requested every 6-12 hours until it can be demonstrated that the magnet has passed through the stomach and it is progressing through the small bowel or beyond.</p> <p>Continuation with imaging will usually be on confirmation of a single magnet being ingested.</p> <p>Urgent report is required. Notify referrer when the image had been reported.</p> <p>External magnetic objects nearby, clothes with metallic buttons or belts with buckle should be removed from the patient.</p>

Appendix 1

Imaging Services

Imaging Advice and Guidance (A & G) :

An Advice and Guidance scheme in Radiology has been in operation since 03/08/20 for GP's to call in and discuss cases of concern. The Imaging A & G service is available for patients who do not nicely fit into any Specialty A&G referral route. Examples for discussion via Imaging A & G – Patient with weight loss, not able to ascribe to any organ system; night sweats; a patient with complex medical issues where an imaging such as a CT scan may help decide further referral routes / management plans. Red flag symptoms should be fast tracked via the appropriate specialty and the GP's should also follow the referral routes for the following pathways:

- Brain Imaging Pathway (Appendix 2)
- Specialist Spinal Triage Service [Orthopaedic Triage Service : Birmingham Community Healthcare \(bhamcommunity.nhs.uk\)](http://OrthopaedicTriageService:BirminghamCommunityHealthcare(bhamcommunity.nhs.uk))
- Ultrasound requests should comply to the BMUS guidelines [Guidance Pages | BMUS](#)
- From 01/04/21, the Advice and Guidance scheme in Radiology will be electronic via eRS, and GP's should select the following service on eRS for Imaging A&G: '*Diagnostic Imaging Advice and Guidance Service – UHB- RRK*'

If it is agreed via the electronic Imaging A&G that a patient requires imaging, it is the responsibility of the GP to refer the patient to Imaging. GP's must attach a copy of the A&G guidance (either as a separate document or copy and paste it onto the Imaging request form) to their referral. Referrals without this attached will be rejected and returned back to the GP as incomplete.

Please see pathway included in the appendices which outlines this process.

GP Information for sending imaging referrals electronically to UHB

Referrals into Radiology at UHB will only be accepted in line with the IRMER regulations under the following criteria and in the following order of preference:

- 1) Requests should originate electronically using:
 - a. UHB PICs for QEHB
 - b. iCARE for BHH, GHH and SOL
- 2) A signed referral may be faxed to the Imaging Department of the appropriate hospital site as follows:
 - a. QEHB: 0121 460 5817
 - b. GHH: 0121 311 1524
 - c. BHH: 0121 424 3083
 - d. SOL: 0121 424 5269
- 3) A signed referral to be sent in the post to the relevant site and department.
- 4) Referrals will be accepted via email using the following email addresses:

For referrals to QEHB:

CT-Bookings@uhb.nhs.uk

Ultrasound-Bookings@uhb.nhs.uk

MRI-Bookings@uhb.nhs.uk
PlainFilm-Bookings@uhb.nhs.uk

For referrals to Heartlands Hospital:
BHHImagingreferrals@uhb.nhs.uk

For referrals to Good Hope Hospital:
GHHImagingreferrals@uhb.nhs.uk

For referrals to Solihull Hospital:
SOLImagingreferrals@uhb.nhs.uk

During this phase of the pandemic, we have endeavoured not to cancel any appointments but delays may have been necessary. As our capacity increases the delays will be reduced with a view to ensuring all patients are invited in a timely manner.

iCare – (Applicable to Heartlands/Good Hope and Solihull Hospitals only)

If you are referring a patient to (UHB) for the first time, a paper referral is required. Please remember to **sign** the referral form and send it directly to the Imaging Department of choice.

Please do not give the paper request to the patients to deliver to the Imaging Department.

After that initial referral, we actively encourage the submission of an electronic referral via iCare Vortal when referring patients to Birmingham Heartlands Hospital, Good Hope Hospital or Solihull Hospital. Instructions on how to acquire a login can be found at the following link:

<https://imaging.heartofengland.nhs.uk/professionals/referrals-results/>

Electronic referral to the Queen Elizabeth Hospital is via the TQUEST system but this is currently **not** available to all practices.

Plain Film – A booking system remains in operation and all valid x-ray requests are given appointments dependant on their urgency. At present we intend to continue this mode of booking in order to manage footfall on all sites.

Ultrasound (US) – All US requests should reflect the new UHB Imaging Guidelines for Ultrasound scans which can be found at:

<https://www.uhb.nhs.uk/gps/referrals/imaging.htm>

Please note: we have not limited gynaecological US scans, e.g. we continue to scan patients with coils for “lost threads”.

CT, MRI or Fluoroscopy - Access to CT, MRI or fluoroscopy (Barium studies) is limited to those listed under Direct Access Pathways below. Please include a form of UHB Advice and Guidance with your request.

Direct Access Pathways

RED FLAG symptoms should be fast tracked via the appropriate speciality.

Except for the Lung Cancer Diagnosis pathway (triggered by an abnormal CXR), all previously existing direct access imaging pathways have been reviewed by both Radiology and CCG representatives. This was to ensure that they were still relevant and that they could be uniformly applied across all UHB sites. Here is an update on those pathways:

Brain Imaging Pathway:

The 2 week wait (2ww) Brain Cancer imaging pathway is not in operation.

For any brain related queries please contact the Neurology Advice and Guidance team at UHB. If brain imaging is warranted the Neurology team will document this in their response along with the degree of urgency. This evidence should be embedded/attached to your Imaging referral and forwarded to the Imaging Department of the patient's local hospital in the usual manner. This pathway serves to encompass the previous headache and 2ww brain cancer pathways. It offers timely neurological support in addition to access to the relevant mode of imaging.

Spinal Pathway:

Primary Care direct access imaging is currently NOT available.

All Spinal referrals from Solihull GP practices should be sent to the UHB Specialist Spinal Triage Service (SSTS) in line with the National Back Pain & Radicular Pain pathway.

The BCHC Spinal Service will accept referrals from all Birmingham GP practices for Cervical, Thoracic and Lumbar spine. Referrals for assessment (not just MRI) should be made via eRS (MSK Service/Spinal Assessment Service) but in case of difficulty, please email a referral letter to: BCHNT.orthopaedics@nhs.net.

All patients for both services will then be contacted directly by a Spinal Triage Practitioner (STP) either by telephone initially or face to face in the future.

The STP's will request MRI imaging if appropriate once a full spinal assessment has been completed.

Requests from GP practices via Radiology A & G **will not** be accepted for this pathway.

Shoulder Pathway:

US shoulder is no longer be available to Primary Care because of the introduction of the evidence based shoulder pathway from BESS (British Elbow and Shoulder Society): [National Guidelines – British Elbow & Shoulder Society \(bess.ac.uk\)](http://bess.ac.uk)

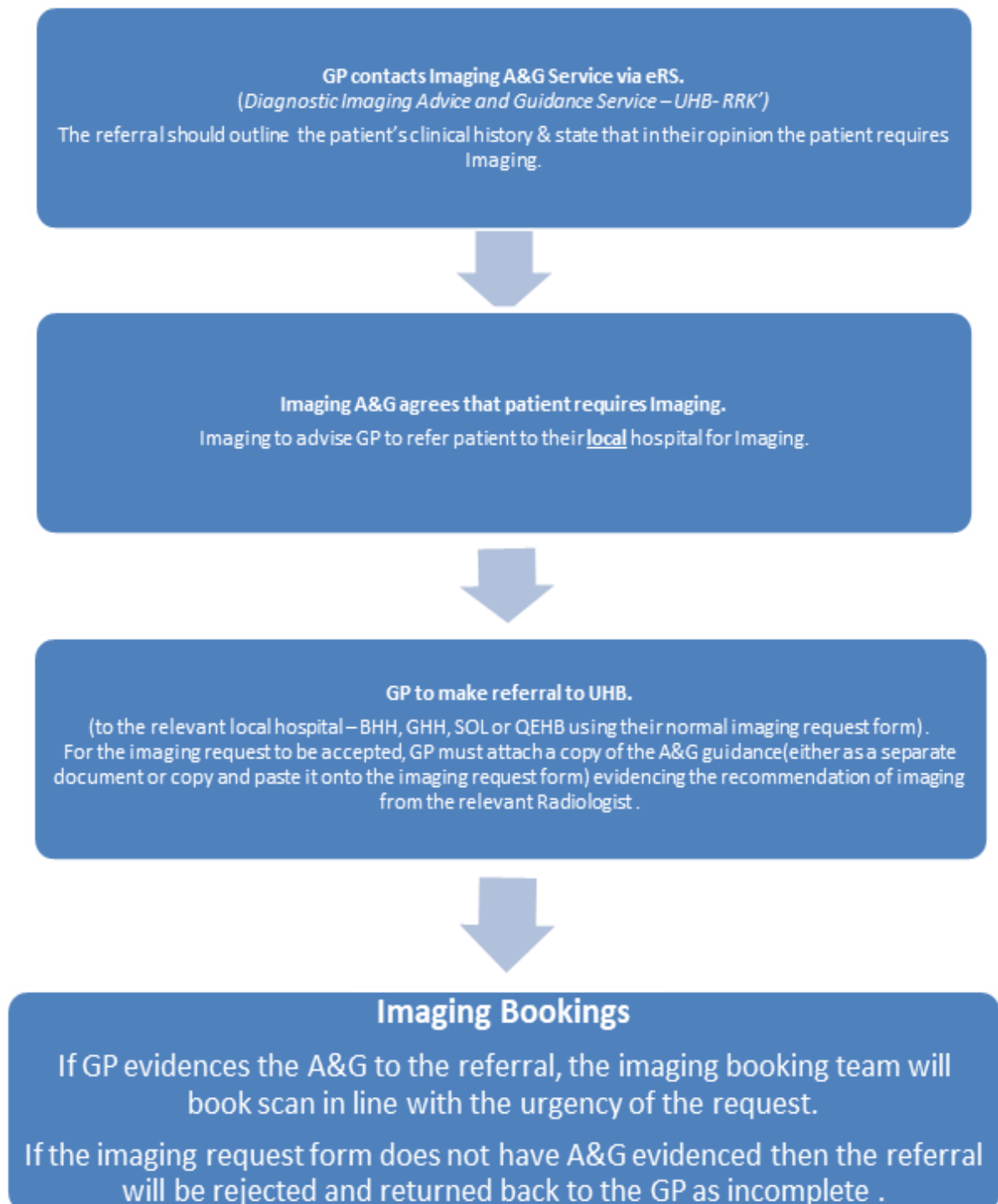
Knee Pathway:

There is no direct access knee imaging pathway in operation with the exception of plain film imaging.

A working group consisting of Radiology, T and O and CCG representatives are scheduled to meet shortly to update this pathway.

Inappropriate imaging requests will be returned to you, unless discussed via the respective Specialty A & G/ Radiology A & G or by following an approved direct access imaging pathway.

Pathway for Imaging Advice and Guidance (A&G).



Appendix 2.

Pathway for Brain Imaging via Neurology Advice and Guidance (A&G).

